

- McKenna DB, Doherty VR, McLaren KM, Hunter JA. Malignant melanoma and lymphoproliferative malignancy: is there a shared aetiology? *Br J Dermatol.* 2000;143:171-173.
- Healy E, Sikkink S, Rees JL. Infrequent mutations of p16^{INK4} in sporadic melanoma. *J Invest Dermatol.* 1996;107:318-321.
- Seeberger H, Starostik P, Schwarz S, et al. Loss of Fas (CD95/APO-1) regulatory function is an important step in early MALT-type lymphoma development. *Lab Invest.* 2001;81:977-986.
- Dierlamm J, Baens M, Wlodarska I, et al. The apoptosis inhibitor gene API2 and a novel 18q gene, MLT, are recurrently rearranged in the t(11;18)(q21;q21) associated with mucosa-associated lymphoid tissue lymphomas. *Blood.* 1999;93:3601-3609.
- Willis TG, Jadayel DM, Du MQ, et al. Bcl10 is involved in t(1;14)(p22;q32) of MALT B cell lymphoma and mutated in multiple tumor types. *Cell.* 1999;96:35-45.

Tadalafil Associated With Anterior Ischemic Optic Neuropathy

Tadalafil (Cialis; Eli Lilly, Indianapolis, Ind) is used to treat erectile dysfunction.¹ Sildenafil (Viagra; Pfizer, New York, NY), a similar medication, has been associated with nonarteritic anterior ischemic optic neuropathy (NAAION).^{2,3} We describe a patient who developed NAAION after he took tadalafil.

Report of a Case. A 59-year-old man with prostate cancer and erectile dysfunction underwent uncomplicated laparoscopic prostatectomy. His only other medical problem was depression, treated with bupropion hydrochloride. The immediate postoperative hematocrit measured 25.2%. The patient was ambulating and hemo-

dynamically stable on postoperative day 1 and that evening took 20 mg of tadalafil. Fifteen hours later, he reported dizziness lasting several minutes. Blood pressure and pulse measured 126/61 mm Hg and 99 bpm, respectively. The episode resolved spontaneously. Forty-five hours after ingesting tadalafil, he noted sudden, persistent "graying" in the inferior visual field of the left eye. The next day, he took 20 mg of tadalafil. The graying did not change.

Examination 6 days later revealed acuity of 20/20 OU, with a left relative afferent pupillary defect. Perimetry (Swedish Interactive Threshold Algorithm Standard 24-2) was normal in the right eye and showed inferior altitudinal loss in the left eye (**Figure 1**). The fundi were normal except for 2 cotton-wool spots in the macula right eye, left optic disc edema, and nerve fiber layer hemorrhage (**Figure 2**). The right optic disc was crowded. The remainder of the examination results were normal. Hematocrit measured 30.2%. Erythrocyte sedimentation rate and C-reactive protein levels were normal. He had no symptoms of temporal arteritis. Six weeks later, acuities and fields were unchanged in each eye, the left optic disc edema was resolving, and no cotton-wool spots were seen.

Comment. Nonarteritic anterior ischemic optic neuropathy developed 45 hours after taking tadalafil. Tadalafil, a phosphodiesterase type 5 inhibitor, enhances erection through

smooth muscle relaxation and increased blood flow in the corpus cavernosum. Forty-five hours is within 2.5 half-lives for a drug that is effective for at least 36 hours, the latest time point tested in clinical trials.¹ In this case, crowded optic discs and postoperative anemia were concurrent risk factors for NAAION.⁴ However, the patient was mobile and asymptomatic prior to taking tadalafil.

Pomeranz et al³ published a case series of NAAION associated with sildenafil, another phosphodiesterase type 5 inhibitor. Sildenafil lowers systemic blood pressure, which could contribute to NAAION. The authors proposed that sildenafil might also contribute to NAAION by vasodilation of the optic disc circulation and interference with vascular autoregulation. Tadalafil acts similarly but is more specific for phosphodiesterase type 5 (found in the corpus cavernosum) and has a longer half-life; also, tadalafil did not lower systemic blood pressure in clinical trials.¹ Nonarteritic anterior ischemic optic neuropathy associated with tadalafil would more likely be due to a local effect on optic disc circulation.

Pomeranz et al³ suggested that patients with a history of unilateral NAAION not use sildenafil. No definite association between tadalafil and NAAION can be made on the basis of the current case. Similarly, the cotton-wool spots might have been related to anemia, tadalafil, or both. However, this case should heighten

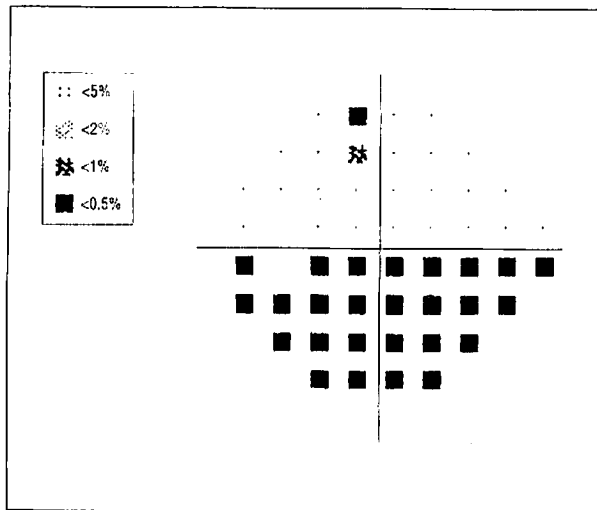


Figure 1. Swedish Interactive Threshold Algorithm Standard 24-2 pattern deviation plot of the left eye. There is inferior altitudinal visual field loss.

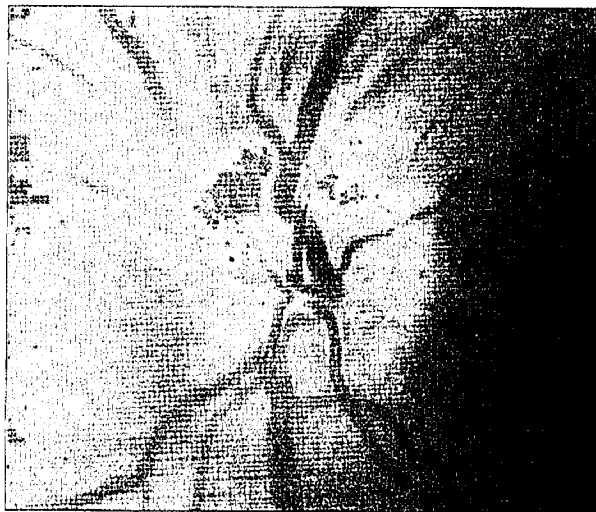


Figure 2. Left optic disc. There is edema and a superior nerve fiber layer hemorrhage.

awareness among ophthalmologists and physicians prescribing tadalafil, especially postoperatively. Further experience with tadalafil will provide data on the validity of an association with NAAION.

George K. Escaravage, Jr, MD
John D. Wright, Jr, MD
Syndee J. Givre, MD, PhD

Financial Disclosure: None.

Correspondence: Dr Givre, Department of Ophthalmology, University of North Carolina at Chapel Hill, 5100 Bioinformatics, CB#7040, Chapel Hill, NC 27599-7040 (givre@med.unc.edu).

1. Cialis [package insert]. Indianapolis, Ind: Eli Lilly & Co; 2003.
2. Egan R, Pomeranz H. Sildenafil (Viagra) associated anterior ischemic optic neuropathy. *Arch Ophthalmol*. 2000;118:291-292.
3. Pomeranz HD, Smith KH, Hart WM Jr, Egan RA. Sildenafil-associated nonarteritic anterior ischemic optic neuropathy. *Ophthalmology*. 2002;109:584-587.
4. Kelman SE. Ischemic optic neuropathies. In: Miller NR, Newman NJ, eds. *Walsh & Hoyt's Clinical Neuro-Ophthalmology*. 5th Edition. Philadelphia, Pa: Lippincott Williams & Wilkins; 1998:549-571.

Recurrent Visual Field Defect and Ischemic Optic Neuropathy Associated With Tadalafil Rechallenge

Tadalafil, a selective cyclic guanosine monophosphate (cGMP)-specific phosphodiesterase type 5 (PDE5) inhibitor, enhances penile erectile function in men. Nitric oxide along with cGMP promotes blood flow to and dilation of smooth muscle in the corpus cavernosum of the penis. Phosphodiesterase type 5 inhibitors prevent degradation of cGMP to potentiate erectile function. Tadalafil (Cialis; Lilly ICOS LLC, Indianapolis, Ind) is one of the PDE5 inhibitors approved for erectile dysfunction, which also include sildenafil citrate (Viagra; Pfizer, Inc, New York, NY) and vardenafil hydrochloride (Levitra; Bayer AG, Leverkusen, Germany, and GlaxoSmithKline, Uxbridge, England).

The package insert for tadalafil describes adverse ophthalmic reactions that include blurred vision, changes in color vision, conjuncti-

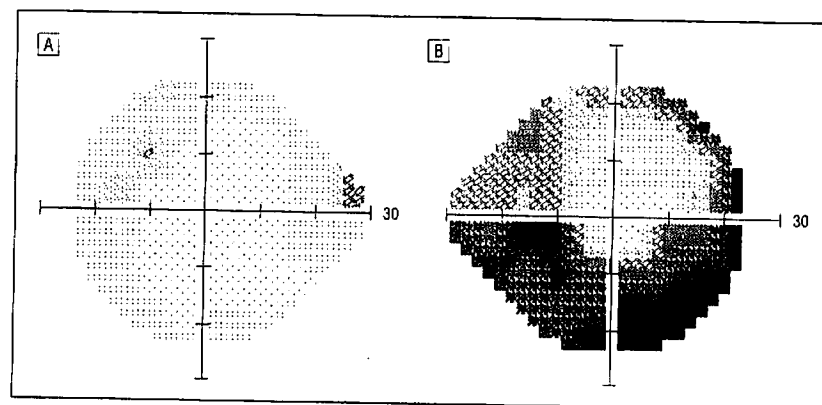


Figure 1. Humphrey visual field results show a normal visual field in the left eye (A) and an inferior altitudinal defect in the right eye (B).

vitis, eye pain, tearing, and swelling of the eyelids. Some reports suggest that sildenafil use may be associated with nonarteritic anterior ischemic optic neuropathy (NAION).¹⁻³ We describe a patient who took tadalafil 5 times in 1 month. He developed transient inferior visual field loss in the right eye within 2 hours of taking the first 4 doses. After the fifth dose, he developed NAION in the right eye with persistent inferior visual field loss.

Report of a Case. A 67-year-old architect with a medical history of hypercholesterolemia sought care because of vision loss. His medications included atorvastatin calcium, aspirin, and folate. He took 20 mg of tadalafil for the first time one morning before sexual intercourse. Within 2 hours, he noted an isolated inferior visual field defect in the right eye that resolved by the time he awoke the following day. On 2 other occasions separated by several days each, he took 20 mg of tadalafil in the morning before sexual intercourse, followed by a similar inferior visual field defect in the right eye that resolved within 24 hours each time. Several days later, he did not achieve an erection after taking 20 mg of tadalafil, but a similar transient inferior visual field defect recurred. Three days later, he took a fifth dose of the drug and participated in sexual intercourse. He noted an inferior visual field defect in the right eye within 2 hours that failed to resolve. He denied systemic symptoms of giant cell arteritis. His erythrocyte sedimentation rate was 5 mm/h.

On examination 14 days later, visual acuities were 20/30 OD and 20/

40 OS. His medical records demonstrated baseline acuities of 20/20 OD and 20/40 OS. A right afferent pupillary defect was present. He identified 10 of 10 Ishihara color plates with each eye. Humphrey visual fields showed an inferior altitudinal visual field defect in the right eye (**Figure 1**). Dilated fundus examination showed hyperemia and edema of the right optic disc (**Figure 2**) consistent with NAION and a normal left optic disc with a small cup-disc ratio. The remainder of his neuro-ophthalmologic examination was unremarkable, including normal, nontender temporal artery pulses.

Comment. The most common optic neuropathy in patients older than 50 years is NAION. Examination results will show a swollen optic nerve and, typically, an altitudinal visual field defect. The pathophysiology underlying NAION is not well understood. Nearly all patients with NAION have a small, crowded optic nerve head ("disc at risk"),⁴ which leads some to believe that a type of compartment syndrome within the confines of the rigid scleral canal may occur.^{4,5} A microvascular ischemic event leads to axoplasmic stasis and edema,⁶ compressing the small capillaries of the optic nerve head.⁷ In older patients these capillaries may exhibit poor autoregulation, leading to more ischemia and axoplasmic stasis. The patient described herein had a disc at risk in the fellow eye, but it is unclear whether PDE5 inhibitors affect optic nerve blood flow.

Several patients have developed NAION between 45 minutes and 12 hours after taking sildenafil, a PDE5

inhibitor, which suggests an association.² In a masked, randomized crossover trial, 15 young, healthy male volunteers (mean age, 39 years) underwent ocular blood flow measurements after oral ingestion of sildenafil citrate, 100 mg.⁸ The authors of that trial suggest that PDE5 inhibitors could affect autoregulation at the optic nerve head. Their patients were all young and healthy, and none developed permanent or transient vision loss. However, in an older, vasculopathic patient with a susceptible disc at risk, sclerotic optic disc vasculature, and poor baseline autoregulation, tadalafil could conceivably cause NAION.

The patient described herein experienced 4 episodes of transient, inferior blurring of the visual field before the NAION event, all occurring within 2 hours of tadalafil ingestion. He did not undergo a formal ophthalmologic examination during the transient visual changes, but these events may have represented transient ischemia to the optic nerve. The rapid onset of symptoms and the close temporal relationship following recurrent drug ingestion support an association between tadalafil use and NAION. Previous reports¹⁻³ described patients with visual field loss occurring once after ingestion of sildenafil. Our patient had visual field loss after multiple rechallenges with tadalafil, providing additional and unique evidence

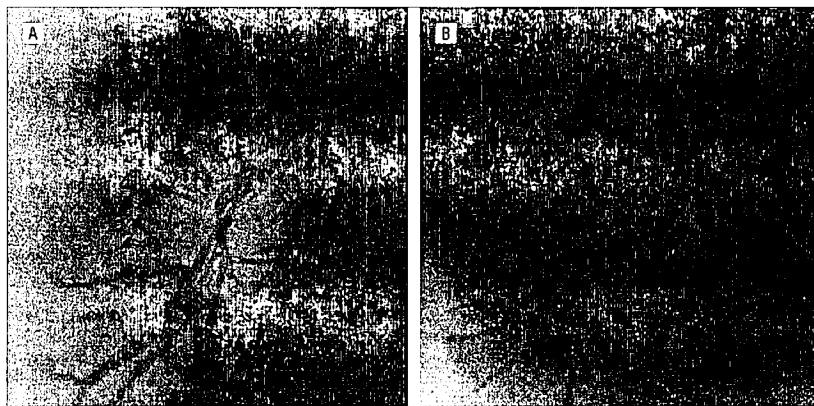


Figure 2. Fundus photographs show a swollen right optic disc (A) and a normal left optic disc with a small cup-disc ratio (B).

that use of PDE5 inhibitors may represent a risk factor for the development of NAION.² Certainly, given the large number of prescriptions dispensed for PDE5 inhibitors and the small number of NAION-associated cases reported, a definite causal link has not been proved. Physicians should inquire about PDE5 inhibitors in patients with NAION and counsel patients about the potential risk of future use for the fellow eye.

Kathryn Bollinger, MD, PhD
Michael S. Lee, MD

Financial Disclosure: None.

Correspondence: Dr Lee, Cole Eye Institute, The Cleveland Clinic Foundation, 9500 Euclid Ave, Desk i-32, Cleveland, OH 44195 (leem4@ccf.org).

1. Cunningham AV, Smith KH. Anterior ischemic optic neuropathy associated with Viagra. *J Neuroophthalmol*. 2001;21:22-25.
2. Pomeranz HD, Smith KH, Hari WM Jr, Egan RA. Sildenafil-associated nonarteritic anterior ischemic optic neuropathy. *Ophthalmology*. 2002; 109:584-587.
3. Egan R, Pomeranz H. Sildenafil (Viagra) associated anterior ischemic optic neuropathy. *Arch Ophthalmol*. 2000;118:291-292.
4. Beck RW, Servais GE, Hayreh SS. Anterior ischemic optic neuropathy. IX: cup-to-disc ratio and its role in pathogenesis. *Ophthalmology*. 1987; 94:1503-1508.
5. Tesser RA, Niendorf ER, Levin LA. The morphology of an infarct in nonarteritic anterior ischemic optic neuropathy. *Ophthalmology*. 2003; 110:2031-2035.
6. McLeod D, Marshall J, Kohner EM. Role of axoplasmic transport in the pathophysiology of ischaemic disc swelling. *Br J Ophthalmol*. 1980; 64:247-261.
7. Hayreh SS. Anterior ischemic optic neuropathy. V: optic disc edema an early sign. *Arch Ophthalmol*. 1981;99:1030-1040.
8. Grunwald JE, Siu KK, Jacob SS, Dupont J. Effect of sildenafil citrate (Viagra) on the ocular circulation. *Am J Ophthalmol*. 2001;131:751-755.